

# Comparison of Two Surgical Techniques for Endoscopic Brow Lift: Bone Tunnel Fixation Versus Temporary Tape Fixation: A Clinical Trial

Shahriar Haddady-Abianeh<sup>1,2</sup>, Javad Rahmati<sup>1,2</sup>, Ali Yavari<sup>1,2</sup>, Changiz Delavari<sup>1,2</sup>,  
Masih Taghipour Arani<sup>1,2</sup>, Hojjat Molaei<sup>1,2\*</sup>

1. Department of Plastic & Reconstructive Surgery, School of Medicine, Tehran University of Medical Sciences, Tehran, Iran
2. Department of Plastic & Reconstructive Surgery, Razi Hospital, Tehran University of Medical Sciences, Tehran, Iran

## ABSTRACT

**Background:** We compared two endoscopic brow lift fixation techniques in a 2023 randomized clinical trial: bone tunnel fixation versus temporary tape fixation. The primary objective was to evaluate the stability of the brow lift over time.

**Methods:** Patients were randomly assigned to either the bone tunnel group or the tape fixation group, where a mesh tape was secured to the scalp and removed 7-10 days post-surgery. In total, 36 individuals participated in the study, including 18 patients in the Taping group and 18 patients in the Bony Fixation group. Pre-operative eyebrow measurements were taken, and patients were followed up at one and nine months to assess outcomes

**Results:** While the bone tunnel technique required a significantly longer surgical time, it was more effective at maintaining the brow lift in both the medial and lateral regions of the eyebrow after nine months. Complication rates were similar between the two groups.

**Conclusion:** Bone tunnel fixation provides superior long-term stability for endoscopic brow lift compared to temporary tape fixation, despite the longer procedure duration. Further research with extended follow-up is recommended to confirm long-term outcomes.

## KEYWORDS

Bone Tunnel Fixation; Temporary Tape Fixation; Clinical Trial

## Please cite this paper as:

Haddady-Abianeh S, Rahmati J, Yavari A, Delavari C, Taghipour Arani M, Molaei H. Comparison of Two Surgical Techniques for Endoscopic Brow Lift: Bone Tunnel Fixation Versus Temporary Tape Fixation: A Clinical Trial. *World J Plast Surg.* 2025;14(4):1-8.  
doi: 10.61186/wjps.14.4.\*\*

## \*Corresponding Author:

Hojjat Molaei

Mahdi Clinic, IKHC, Bagherkhan St., Towhid Sq., Tehran, Iran

Tel.: +989127798804

Email: [hmgprs@gmail.com](mailto:hmgprs@gmail.com)

Received: \*\*\*

Accepted: \*\*\*

## INTRODUCTION

Brow lift is a crucial technique in cosmetic surgery that aids in the alleviating signs of aging in the upper third of the face. Since its initial description by Passot in 1919, this technique has undergone numerous progressive refinements<sup>1</sup>. The latest endoscopic brow lift technique utilizes a markedly different mechanism compared to previous methods to achieve its effects. The endoscopic brow lift technique, in fact, enables

the separation and repositioning of the periosteum at the orbital rims and the zygomatic-maxillary region to elevate the brow<sup>2</sup>. Generally, temporal region dissection and fixation have been standardized and widely accepted.

However, various methods for forehead dissection are available, including subperiosteal and subgaleal dissection. The long-term positioning of the brow remains unpredictable; not all patients retain the correction observed during surgery<sup>3,4</sup>. These factors provided a compelling rationale for modifications in the technique, specifically in fixation. However, bony fixation in the forehead region remains a subject of debate. Indeed, one of the most challenging and contentious aspects of forehead and brow lifts is the fixation and stabilization of the outcome<sup>5</sup>. Although numerous techniques have been introduced for this purpose, there is even disagreement over whether fixation is necessary at all.

A wide range of opinions has been presented in different studies, varying from the belief that complete release and adequate muscle balance without fixation are sufficient, to the assertion that permanent fixation is essential<sup>6</sup>. A study showed that if the periosteum was properly released and the depressor muscles of the brow were severed, the brow assumed a higher position within two months postoperatively. Therefore, in cases where a vertical increase in brow height of more than 4 millimeters is not required, scalp fixation is not essential for achieving a natural result, and there is no significant difference in one-year outcomes when compared to procedures without fixation<sup>7</sup>. However, another study examined alternative brow fixation techniques. They followed 300 patients who underwent endoscopic brow lifts using absorbable subperiosteal sutures for fixation over a six-year period<sup>8</sup>. The study reported satisfactory rejuvenation in all patients, with successful correction of brow movement. The long-term six-year results confirmed the stability and durability of this fixation method. Various fixation methods include tissue sutures, bone screws and plates, absorbable screws, bone tunnels, localized skin excision, temporal muscle exposure to enhance outcomes, tissue glue, and tight head wraps<sup>9</sup>.

We aimed to determine and compare the extent of brow elevation achieved through endoscopic brow lift surgery using bone tunnel fixation and temporary fixation with taping.

## MATERIAL AND METHODS

This study was conducted as a randomized clinical trial (RCT) involving patients who underwent endoscopic brow lift surgery in 2023 at Imam Khomeini Hospital, Tehran, Iran and a private prospective center in Tehran.

This study was approved by the Institutional Review Board (IRB) of our University of Medical Sciences (Approval Code: IR.TUMS.IKHC.REC.1402.126). All patients were informed about the purpose of the study and provided verbal consent to participate.

Participants were adults aged between 30 and 65 years who were candidates for endoscopic brow lift surgery and agreed to participate in the research. Patients were excluded if they had thick skin, deep forehead wrinkles, excessive forehead curvature, any forehead deformities, marked eyebrow asymmetry, tattoos in the upper brow area, a high or receding hairline, a history of forehead trauma or surgery, a prior forehead lift, or a Botox injection within the last four months. Randomization was carried out using a block randomization method with blocks of four to ensure equal distribution between the two groups. The randomization sequence was generated online via Randomization.com by an independent researcher not involved in the surgical procedures. Group allocations were sealed in opaque, sequentially numbered envelopes and opened only after the patient entered the operating room. This approach-maintained allocation concealment throughout the study.

Because the interventions involved surgical procedures, blinding of the surgeon and patients was not possible. However, blinding was implemented for outcome assessment and statistical analysis. The individual responsible for performing postoperative measurements and the statistician analyzing the data were unaware of the participants' group assignments. In addition, all preoperative and postoperative photographs were coded and de-identified before measurement to prevent recognition of the treatment method. The sample size was determined based on data reported by Carl Troilius<sup>7</sup>, where the mean lateral canthal brow (LCB) elevation was  $2.5 \pm 0.775$  mm in the fixation group and  $5.6 \pm 3.5$  mm in the non-fixation group. Using a significance level of 0.05 and a power of 90%, the required sample size was calculated as 32 participants (16 per group).

To account for possible loss to follow-up, the total sample size was increased to 36 patients, resulting in 18 participants in each group.

All surgeries were performed by the same experienced plastic surgeon using a uniform endoscopic brow lift technique. The two groups differed only in the fixation method. In both groups, after infiltration with tumescent solution, four scalp incisions were made posterior to the hairline—two temporal and two paramedian—to allow access for subperiosteal dissection of the forehead. The supraorbital, supratrochlear, and frontal branches of the facial nerve were carefully preserved under endoscopic visualization. The corrugator and procerus muscles were completely released through blunt dissection. In the bony fixation group, fixation was achieved by creating small bone tunnels at the paramedian incision sites, through which PDO 2-0 sutures were passed and secured. In the taping group, after dissection, temporary fixation was applied using a mesh adhesive tape stretched across the forehead and anchored to the scalp at the vertex with skin staples. The tape was removed between seven and ten days postoperatively. All other aspects of preoperative preparation, intraoperative management, and postoperative care were identical in both groups.

Standardized digital photographs were obtained preoperatively and at one and nine months after surgery using the same camera, lighting, and focal distance (1:1 ratio). All imaging was performed by a single technician at a specialized center (Tebnegaar). Measurements included the distance from the pupil, inner canthus, and outer canthus to the upper brow border, recorded in millimeters using a digital screen caliper by a blinded assessor. Representative preoperative and postoperative photographs will be included in the final version of the manuscript to visually demonstrate the surgical results. Patient data, including demographic characteristics, operative time, and postoperative outcomes, were recorded in a structured questionnaire. Surgical duration was measured with a stopwatch from the first incision to the end of wound closure. Patients were followed up at one and nine months postoperatively, and any complications—such as infection, hematoma, hair loss, paresthesia, bone injury, wound dehiscence, or intracranial hemorrhage—were documented.

Statistical analyses were performed using SPSS software version 22 (IBM Corp., Armonk, NY,

USA). Quantitative data were expressed as means and standard deviations, while qualitative data were reported as frequencies and percentages. The normality of continuous variables was examined using the Shapiro–Wilk test. Between-group comparisons at baseline were analyzed using independent-samples t-tests for normally distributed variables and the Mann–Whitney U test for non-normal data. Categorical variables were compared using the chi-square or Fisher's exact test, as appropriate.

Changes in brow position across the three time points (preoperative, one month postoperative, and nine months postoperative) were analyzed using repeated-measures analysis of variance (ANOVA) within the general linear model framework. Mauchly's test was used to assess the assumption of sphericity, and if violated, the Greenhouse–Geisser correction was applied. Main effects of time, group, and the time-by-group interaction were examined to assess both within-group improvements and between-group differences over time. A *p*-value of less than 0.05 was considered statistically significant.

## RESULTS

In total, 36 individuals participated in the study, including 18 patients in the Taping group and 18 patients in the Bony Fixation group. The cohort comprised 69.4% women and 31.6% men. The mean age of the participants was  $48.4 \pm 8.8$  years, ranging from 35 to 66 years. There were no statistically significant differences between the two groups in terms of mean age ( $p = 0.86$ ) or gender distribution. Before surgery, the measured distances at the medial, middle, and lateral areas of both the right and left eyes were comparable between groups, with no statistically significant differences observed in any parameter (all  $P > 0.05$ ) (Table 1).

To examine the changes observed postoperatively in the two study groups, the Repeated Measures test was employed, and the General Linear Model was used for a more detailed analysis of differences over multiple time points. In these models, the assumption of sphericity for assessing the equality of variances-covariances of the observations was not met, as indicated by the Mauchly's test ( $P$ -value  $< 0.05$ ). Since the  $P$ -values from Mauchly's test were less than 0.05 for all variables, the Greenhouse–Geisser correction was applied to adjust for the

violation of sphericity (Table 2).

When examining the two groups separately, significant differences in brow lift measurements (in millimeters) at the medial side of the right eye were observed between preoperative, one month postoperative, and nine months postoperative time points ( $P$ -value < 0.05). Regardless of the type of surgery performed, both groups showed statistically significant changes in brow lift measurements at the medial side of the right eye from preoperative to one month and nine months postoperative. This indicates that in both groups, significant statistical changes in brow lift at the medial right eye area occurred over time.

Regarding the variable of Group/Time, no statistically significant differences were found between the two groups. Additionally, given that the interaction effect of time on the mean change

in millimeters between the intervention and control groups was not significant ( $P$ -value < 0.05) (see the table for Group/Time changes), the trend of changes in measured distances over time was similar between the two groups. There was no statistically significant difference between the groups over time. When simultaneously examining the two variables of Group and Time, there was no significant statistical change between the groups.

When examining the two groups separately, significant differences were observed in brow lift measurements (in millimeters) at the medial and lateral sides of the right eye between preoperative, one month postoperative, and nine months postoperative time points in both groups ( $P$ -value < 0.05). Regarding the variable of Group/Time, the changes within each group over time showed significant statistical differences.

**Table 1.** Basic characteristics of study groups

Variable	Taping group (n=18)	Bony Fixation group (n=18)	Total (n=36)	<i>P</i> -value
Age (yr)	47.83±9.66	49.04±8.06	48.43±8.78	0.86
<b>Sex, n (%)</b>				-
Male	6 (33%)	5 (28%)	11 (31.6%)	-
female	12 (67%)	13 (72%)	25 (69.4%)	-
Right medial	1.54±0.11	1.54±0.12	1.54±0.11	N/A
Right middle	1.72±0.09	1.74±0.09	1.73±0.09	0.50
Right lateral	1.84±0.09	1.89±0.09	1.86±0.9	0.22
Left medial	1.55±0.12	1.55±0.11	1.54±0.11	0.92
Left middle	1.73±0.08	1.72±0.09	1.72±	0.92
Left lateral	1.84±0.09	1.87±0.08	1.85±0.09	0.27

**Table 2.** Statistical significance and changes in right eye measurements by time, group/time, and group

Variable	Time, Group/Time, Group	Degrees of Freedom	Sum of Squares	Mean Squares	F-value	<i>p</i> -value
Right med	Greenhouse-Geisser Test - Time	1.436	1.886	1.313	77.645	0.001
	Greenhouse-Geisser Test – Group/Time	1.436	0.016	0.011	0.644	0.48
	Tests of Between-Subjects Effects - Group	1	0.039	0.039	0.961	0.334
Right mid	Greenhouse-Geisser Test - Time	1.279	6.092	4.763	520.9	0.001
	Greenhouse-Geisser Test – Group/Time	1.279	0.193	0.151	16.533	0.001
	Tests of Between-Subjects Effects - Group	1	0.566	0.566	9.528	0.004
Right lateral	Greenhouse-Geisser Test - Time	1.351	9.454	6.996	989.723	0.001
	Greenhouse-Geisser Test – Group/Time	1.351	0.083	0.061	8.667	0.002
	Tests of Between-Subjects Effects - Group	1	0.377	0.377	8.321	0.007

In comparing the two groups, significant differences were observed in brow lift measurements (in millimeters) at the medial and lateral sides of the right eye at preoperative, one month postoperative, and nine months postoperative time points. The bone fixation group demonstrated superior results compared to the temporary fixation group, with statistical significance (Table 3).

When examining the two groups separately, significant differences were observed in brow lift measurements (in millimeters) at the medial side of the left eye between preoperative, one month postoperative, and nine months postoperative time points in both groups ( $P$ -value  $< 0.05$ ). However, regarding the Group/Time variable, the changes within each group over time did not show significant statistical differences ( $P$ -value  $< 0.05$ ). Additionally, since the interaction effect of time on the mean change in millimeters between the intervention and control groups was not significant (Table 3), the trend of changes in the measured distances over time was consistent between the two groups, with no significant statistical differences observed between them over time (Figure 1).

In comparing the two groups, no statistically significant differences were observed in brow lift measurements (in millimeters) at the medial side of the left eye between preoperative, one month postoperative, and nine months postoperative time points.

Given the small number of male patients in both groups compared to the number of female patients, conducting a statistical test to assess differences in lift measurements between genders was not

sufficiently reliable. Regarding the duration of surgery, the taping method was associated with a shorter operative time, and this difference was statistically significant. In terms of postoperative complications, no complications were observed in either group except for paresthesia. The incidence of paresthesia did not differ significantly between the two groups.

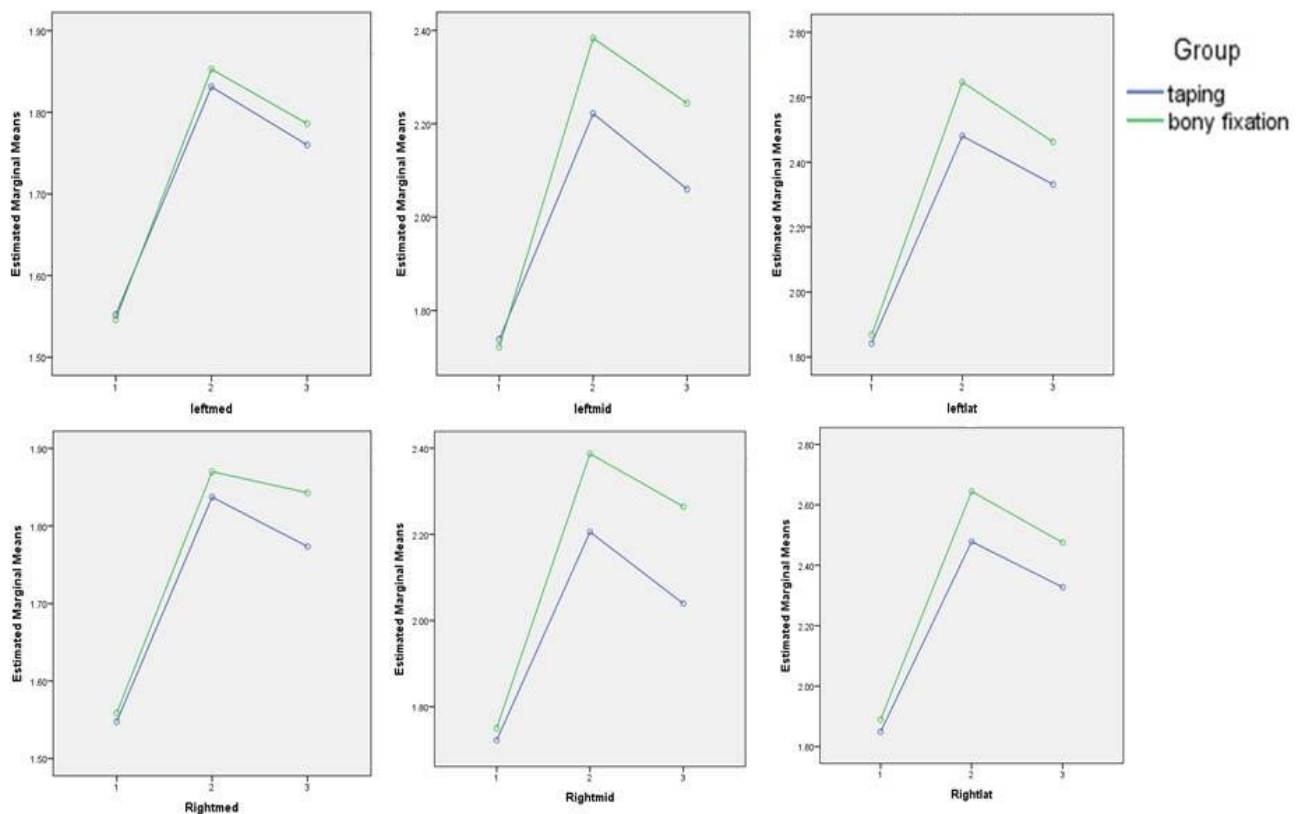
## DISCUSSION

Based on the results of this study, the bone tunnel fixation method required a longer operative time. At the nine-month postoperative mark, no statistically significant differences were observed in the mean and standard deviation of the measured distances at the “medial” aspect of both the right and left eyes between the two groups. However, in the middle and lateral aspects of both eyes, the bone tunnel fixation method demonstrated statistically significant advantages over the taping method. The complication rates between the two methods showed no significant differences.

In recent years, the endoscopic technique has been increasingly accepted as a minimally invasive approach for brow lift procedures compared to other open surgical methods<sup>10-12</sup>. However, the specific need for and the method of brow fixation to ensure the longevity of the endoscopic brow lift remains a topic of ongoing debate. Proponents of fixation argue that internal stabilization techniques in endoscopic brow lifts provide long-term support to maintain the elevated position of the brows and soft tissue during the wound healing phase<sup>11</sup>. These

**Table 3.** Statistical significance and changes in left eye measurements by time, group/time, and group

Variable	Time, Group/Time, Group	Degrees of Freedom	Sum of Squares	Mean Squares	F-value	P-value
Left med	Greenhouse-Geisser Test - Time	1.51	1.687	1.118	250.024	<0.001
	Greenhouse-Geisser Test – Group/Time	1.51	0.005	0.004	0.813	0.418
	Tests of Between-Subjects Effects - Group	1	0.005	0.005	0.157	0.694
Left mid	Greenhouse-Geisser Test - Time	1.312	6.342	4.835	532.833	<0.001
	Greenhouse-Geisser Test – Group/Time	1.312	0.218	0.166	18.28	<0.001
	Tests of Between-Subjects Effects - Group	1	0.325	0.325	6.934	0.013
Left lateral	Greenhouse-Geisser Test - Time	1.378	9.886	7.175	717.753	<0.001
	Greenhouse-Geisser Test – Group/Time	0.95	1.378	0.069	6.878	0.006
	Tests of Between-Subjects Effects - Group	1	0.315	0.315	9.716	0.004



**Figure 1.** Comparison of the differences in distances at the medial, middle, and lateral aspects of the left and right eyes at three time points (preoperative, 1 month postoperative, and 9 months postoperative) between the two study groups

internal stabilization techniques employ various methods of fixation. In this study, we compared two such methods: fixation through a bone tunnel and temporary fixation using taping, over a nine-month period. In a study<sup>13</sup>, a four-year follow-up of patients who underwent endoscopic brow lift with fixation through a bone tunnel demonstrated that the brow elevation remained at a minimum of 5 millimeters after four years. Additionally, bone tunnel fixation techniques are characterized by low implant profiles and minimal palpability, leading to high levels of satisfaction among both surgeons and patients, as well as greater durability<sup>14</sup>. These findings corroborate the results of our study. On the other hand, creating bone tunnels, while effective, may be technically more challenging and, as a result, might require longer operative times compared to temporary methods<sup>15</sup>. Our study also confirms this observation. In achieving an ideal brow lift, four key characteristics are essential for obtaining a desirable outcome: durability, patient

comfort, ease of use during surgery, and the absence of postoperative complications<sup>15</sup>.

To achieve a pleasing and lasting outcome, the fixation method must not only provide greater durability but also ensure ease of use for the surgeon. Considering all four characteristics can result in shorter operative times, fewer postoperative complications, and reduced overall operating room costs<sup>16</sup>. On the other hand, the fixation method should be low-risk for the patient, stable, and absorbable, eliminating the need for removal while remaining in place long enough to allow tissue-fixator integration. This is crucial as a minimum of 6 to 12 weeks is required for the periosteum to adhere to the calvarium<sup>8</sup>. Endoscopic brow lift with fixation using Endotine yielded acceptable results over a two-year follow-up period, comparable to other fixation methods, while offering greater ease of use and fewer postoperative complications<sup>17</sup>.

In a one-year follow-up, endoscopic brow lift using Endotine not only achieved a 95% patient

satisfaction rate but also led surgeons to prefer this method for its ease of use<sup>18</sup>. Thus, when evaluating the efficacy of surgical techniques, it is essential to consider factors beyond long-term effectiveness. Success in modern brow lift surgery involves not just elevating the brows but also enhancing or maintaining their shape. Consequently, the term “brow lift” may be a misnomer, and a more appropriate term might be “brow contouring.” Even if the amount of height change is not substantial, enhancing the shape of the brow is often sufficient to improve the patient’s psychological well-being according to established criteria<sup>19</sup>. Therefore, surgeons should consider using the taping fixation method, which offers shorter operative times and acceptable clinical outcomes along with high patient satisfaction.

One of the limitations of our study was the following-up period of less than one year, as results might vary over a longer time frame. It is recommended that future studies consider follow-up periods extending beyond one year to better assess the long-term outcomes.

## CONCLUSION

Although the bone tunnel fixation method demonstrated superior effectiveness in maintaining brow lift stability after 9 months compared to the taping method, it also resulted in a longer operative time. Therefore, surgeons should consider the taping fixation method, which offers shorter operative times and acceptable clinical outcomes for patients. Future studies should consider increasing the sample size for both genders and extending the follow-up period to compare the long-term outcomes of these two methods across both sexes. Additionally, it is recommended to replace the temporary fixation method in the control group with a non-fixation approach and compare it against both temporary fixation and bone fixation methods. Moreover, incorporating patient satisfaction questionnaires alongside clinical outcomes would provide a more comprehensive evaluation of patient satisfaction and should be included in future research.

## ACKNOWLEDGMENTS

No financial support was received.

## CONFLICT OF INTERESTS

The authors declare that they have no conflict of interest.

## REFERENCES

1. Cho MJ, Carboy JA, Rohrich RJ. Complications in Brow Lifts: A Systemic Review of Surgical and Nonsurgical Brow Rejuvenations. *Plast Reconstr Surg Glob Open* 2018 Oct;**6**(10):e1943.
2. Raggio BS, Winters R. Endoscopic Brow Lift. StatPearls. Treasure Island (FL): StatPearls Publishing Copyright © 2025, StatPearls Publishing LLC.; 2025.
3. Nassif PS, Kokoska MS, Homan S, Cooper MH, Thomas JR. Comparison of Subperiosteal vs Subgaleal Elevation Techniques Used in Forehead Lifts. *Archives of Otolaryngology-Head & Neck Surgery* 1998;**124**(11):1209-15.
4. Nassif PS, Kokoska MS, Homan S, Cooper MH, Thomas JR. Comparison of subperiosteal vs subgaleal elevation techniques used in forehead lifts. *Arch Otolaryngol Head Neck Surg* 1998 Nov;**124**(11):1209-15.
5. Pascali M, Bocchini I, Avantaggiato A, Cervelli V. 2014 SICPRE Proceedings: Meeting Proceedings. *Plast Reconstr Surg Glob Open* 2015 Mar;**3**(3).
6. Karimi N, Kashkouli MB, Sianati H, Khademi B. Techniques of Eyebrow Lifting: A Narrative Review. *J Ophthalmic Vis Res* 2020 Apr-Jun;**15**(2):218-35.
7. Troilius C. Subperiosteal brow lifts without fixation. *Plast Reconstr Surg* 2004 Nov;**114**(6):1595-603; discussion 604-5.
8. Foustanos A. Suture fixation technique for endoscopic brow lift. *Semin Plast Surg* 2008 Feb;**22**(1):43-9.
9. Pascali M, Avantaggiato A, Bocchini I, Carinci F, Cervelli V. Comparison among three different fixation techniques in temporal brow lift surgery. *J Craniofac Surg* 2015 May;**26**(3):906-10.
10. Puig CM, LaFerriere KA. A retrospective comparison of open and endoscopic brow-lifts. *Arch Facial Plast Surg* 2002 Oct-Dec;**4**(4):221-5.
11. Caceres H, Raza SN, Katta T, et al. Fixation Techniques Across Endoscopic Brow Lifts: A Scoping Review. *Aesthetic Plast Surg* 2025 Aug 13.
12. Chasan PE, Hauch AT. The K-Wire Fixation Technique for Endoscopic Brow Lift: A Long-Term Follow-Up. *Aesthet Surg J* 2020 Sep 14;**40**(10):1051-60.
13. Jones BM, Grover R. Endoscopic brow lift: a personal review of 538 patients and comparison of fixation techniques. *Plast Reconstr Surg* 2004 Apr 1;**113**(4):1242-50; discussion 51-2.
14. Şibar S, Dikmen AU, Erdal AI. Long-term Stability

- in Endoscopic Brow Lift: A Systematic Review and Meta-Analysis of the Literature. *Aesthet Surg J* 2025 Feb 18;**45**(3):232-40.
15. Raggio BS, Winters R. Endoscopic brow lift. 2019.
16. Hönig JF, Frank MH, Knutti D, de La Fuente A. Video endoscopic-assisted brow lift: comparison of the eyebrow position after Endotine tissue fixation versus suture fixation. *J Craniofac Surg* 2008 Jul;**19**(4):1140-7.
17. Liu RH, Kim M, Lindsay RW. Short-Term Outcomes of Endoscopic Brow Lifting Without Depressor Resection. *Laryngoscope* 2025 Aug 18.
18. Chowdhury S, Malhotra R, Smith R, Arnstein P. Patient and surgeon experience with the endotine forehead device for brow and forehead lift. *Ophthalmic Plast Reconstr Surg* 2007 Sep-Oct;**23**(5):358-62.
19. Wang T, Li Y, Pang M. Evaluation of morphological and psychological outcomes after sub-brow blepharoplasty. *Front Surg* 2025;**12**:1658806.